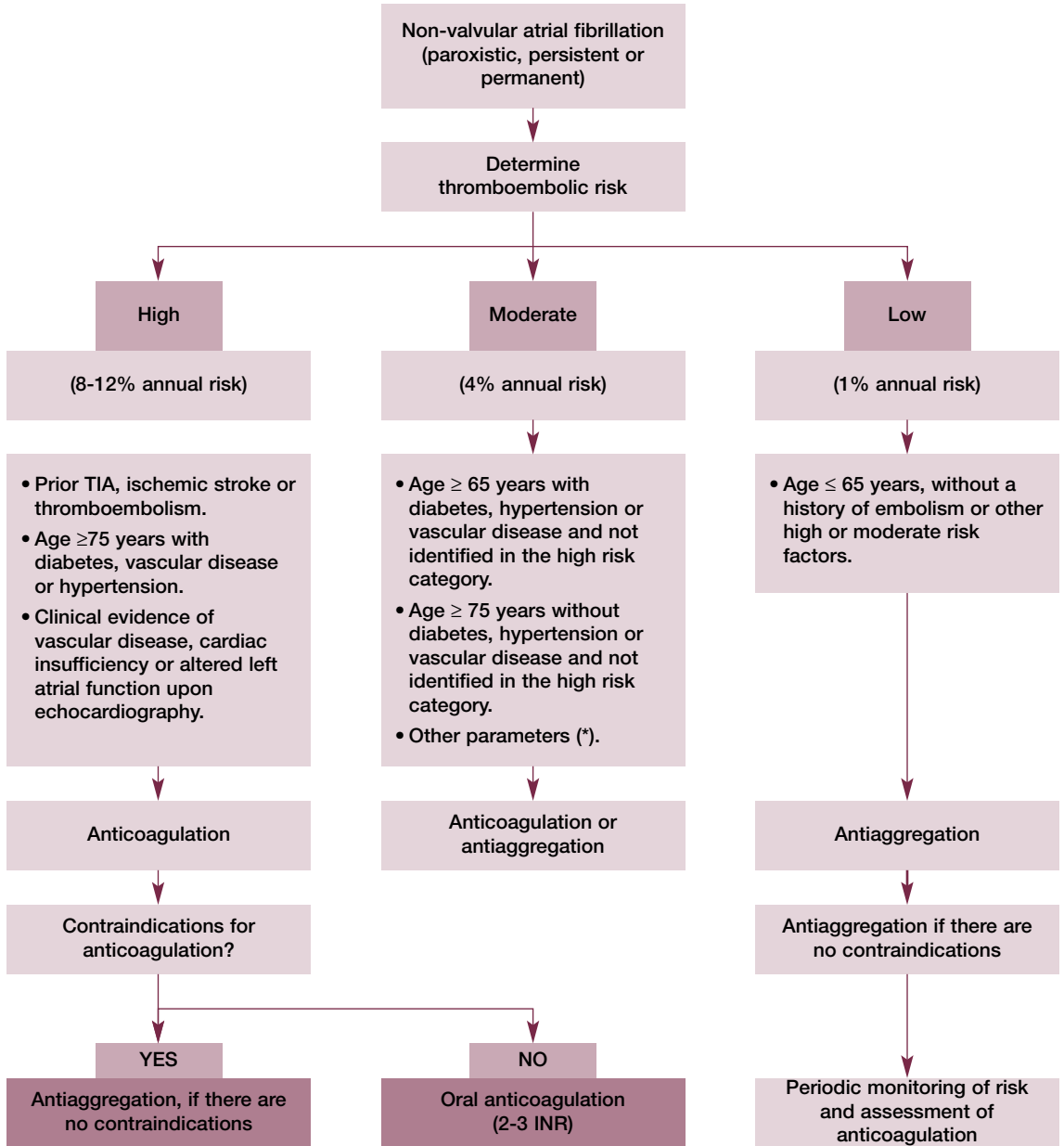


Figure 4. Algorithm of antithrombotic treatment management in patients with non-valvular atrial fibrillation³⁶⁷



* Certain patients classified as presenting moderate risk, with any of the following parameters obtained by echocardiography, such as increased size of the left atrium, the presence of dense contrast medium in the atrium or the presence of an altered cardiac structure with no ventricular dysfunction should be considered for treatment with oral anticoagulants.